



PATIENT

Griffin Harri

PRESENTING CLINICAL SIGNS

Presented for vomiting and inappetence. Normal labs aside from mild hypokalemia. Has eaten nerf darts in the past

SPECIES

Canine

ULTRASONOGRAPHIC EXAMINATION OF THE ABDOMEN

Urinary System

The urinary bladder, trigone, cystourethral junction, and visible pelvic urethra exhibited normal thickness and tone. Anechoic urine was present in the lumen with mild non-dependent particulate sediment. The ureteral papillae were normal. The ureters were not visible which is normal. No evidence of inflammatory or neoplastic changes was noted.

BREED

Aussie Doodle

SEX

MN

Normal size and margination were present in the kidneys. A normal 1:3 cortex / medulla ratio and normal corticomedullary definition were maintained. The echogenicity of the cortex was similar to or slightly less than normal liver parenchyma while the medulla echogenicity was hypoechoic to the cortex with no evidence of pelvic dilation. The left kidney measured 4.6 cm in length. The right kidney measured 4.8 cm in length.

AGE

3yr

The area of the aortic trifurcation was free of pathology.

The residual prostate appeared normal and free of pathology

WEIGHT

8.1kg

Adrenal Glands

The left adrenal gland was uniform in size and contour with a uniformly hypoechoic parenchyma. The left adrenal gland measured 0.42 cm width at the caudal pole. The right adrenal gland was uniform in size and contour with a uniformly hypoechoic parenchyma. The right adrenal gland measured 0.43 cm width at the caudal pole.

INTERPRETED BY

R. McKenzie Daniel,
DVM, DABVP
(Canine and Feline)

Spleen

The spleen exhibited a finely textured and homogenous parenchyma which was hyperechoic to the liver and renal cortical parenchyma. The capsule was smooth and regular without apparent expansion. The splenic vasculature at the hilus was normal in volume with no evidence of congestion or thrombosis. Acute to chronic inflammatory, neoplastic, or benign parenchyma changes were not noted.

IMAGING PERFORMED BY

Dr Sarah Barthelemy

Liver/Gallbladder

The liver was subjectively normal in size, structure, and contour. The liver parenchyma was uniform and hypoechoic to the spleen with a mild coarse echotexture. Normal vascular volume. The hepatic and portal vasculature were normal in appearance without signs of congestion. The gallbladder was non-distended in size with thin walls and mild non-organized debris. The cystic and common bile ducts were normal.

HOSPITAL NAME

Fish Creek Pet Hospital

REFERRING VET

Dr McKay

Gastrointestinal

The stomach presented normal to regional mild thickened wall secondary to echogenic mucosa hypertrophy. Intact wall layering was maintained and distinct. Mild gastric distension with primarily anechoic fluid and lumen gas was present. No evidence of shadowing gastric echo, overt foreign material or mechanical pyloric outflow obstruction.

INVOICE 23610

DATE

01/19/2026



PATIENT

Griffin Harri

A mid abdomen intestinal strongly shadowing echo consistent with jejunal foreign body was present, potentially measuring 4.4 cm in length. Mild associated proximal segmental duodenal and jejunal ileus with subjective empty small intestine distal. Mild associated probable inflammatory intestinal mural changes in the area of the jejunal foreign body.

SPECIES

Canine

Normal visible colon wall layers were present with semi formed to soft feces in lumen.

Pancreas

BREED

Aussie Doodle

The parenchyma of the left limb, body and right limb of the pancreas presented isoechoic to the adjacent omental fat. A normal curvilinear capsule contour of the pancreas was present. The visible pancreatic duct was normal. No signs of active inflammation or neoplastic disease was evident.

Free Abdomen

SEX

MN

Intermittent mildly prominent to enlarged mesenteric lymph nodes were present. The lymph nodes were essentially isoechoic to adjacent omentum without evidence of peripheral inflammation and maintaining a normal width: length ratio (<0.5). An example measured 1.8 cm x 0.6 cm.

AGE

3yr

Mild peri-intestinal hyperechoic omentum and scant pockets of peritoneal effusion were present.

ULTRASONOGRAPHIC FINDINGS

Primary

WEIGHT

8.1kg

- Non-obstructive to mild partially obstructive jejunal foreign body, mild associated probable inflammatory jejunal mural changes, peri-intestinal reactive omentum, mild benign mesenteric lymphadenopathy and scant peritoneal effusion
- Hypomotile gastritis.
- Semi-formed to soft fecal matter in colon.

INTERPRETED BY

R. McKenzie Daniel,
DVM, DABVP
(Canine and Feline)

INTERPRETATION OF THE FINDINGS & FURTHER RECOMMENDATIONS

Exploratory laparotomy with gross inspection of the gastrointestinal tract and expectation toward enterotomy is recommended. Additional areas of gastrointestinal foreign material was not obvious. Potential for resection anastomosis of segmental jejunum in the area of the foreign body thought unlikely yet not definitively excluded. Pending gross inspection, concurrent intestinal biopsies given repeated pica to assess underlying intestinal disease at the time of surgery is suggested.

IMAGING PERFORMED BY

Dr Sarah Barthelemy

HOSPITAL NAME

Fish Creek Pet Hospital

REFERRING VET

Dr McKay

INVOICE

23610

DATE

01/19/2026



PATIENT

Griffin Harri

SPECIES

Canine

BREED

Aussie Doodle

SEX

MN

AGE

3yr

WEIGHT

8.1kg

INTERPRETED BY

R. McKenzie Daniel,
DVM, DABVP
(Canine and Feline)

IMAGING PERFORMED BY

Dr Sarah Barthelemy

HOSPITAL NAME

Fish Creek Pet Hospital

REFERRING VET

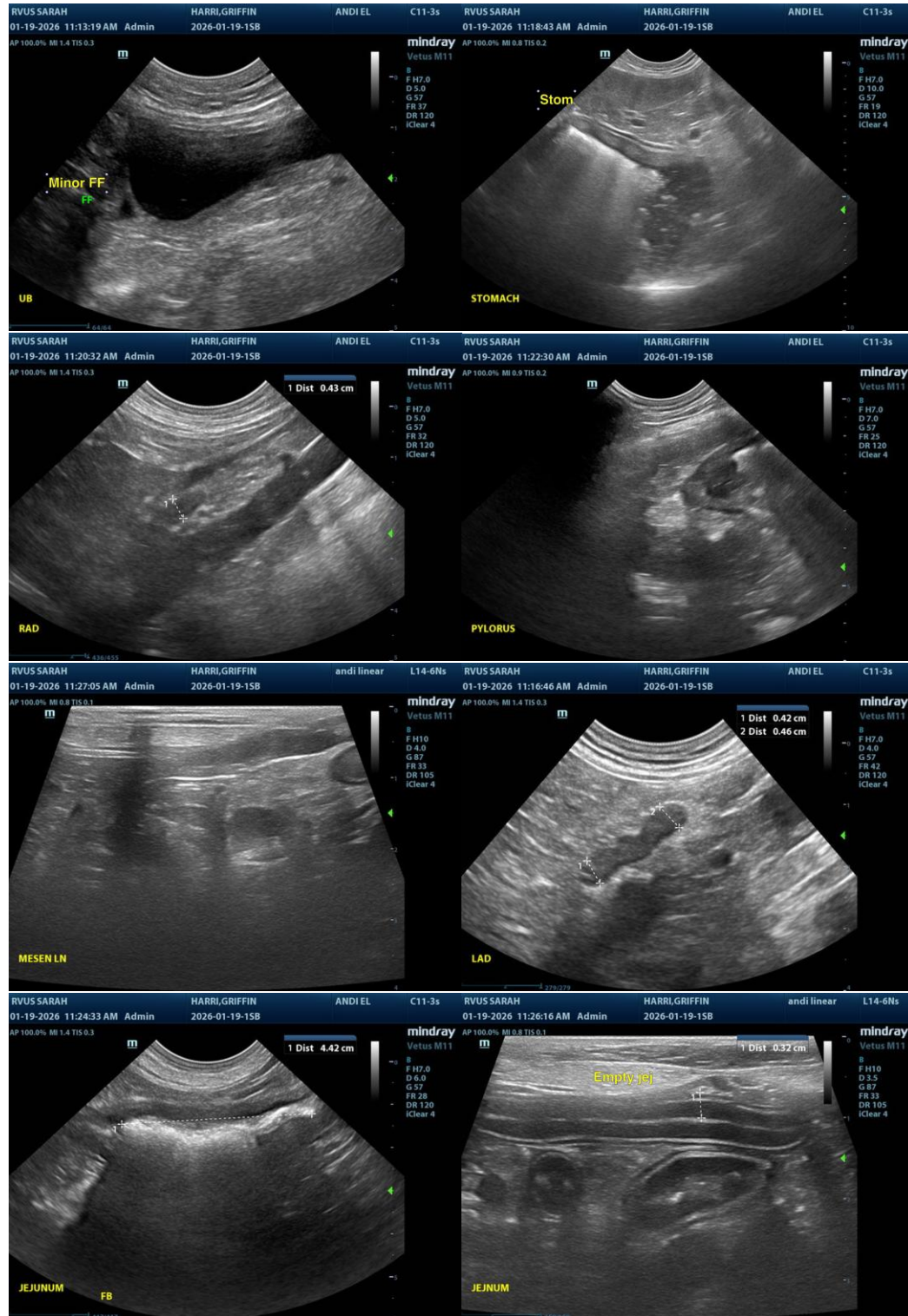
Dr McKay

INVOICE

23610

DATE

01/19/2026





PATIENT

Griffin Harri

SPECIES

Canine

BREED

Aussie Doodle

SEX

MN

AGE

3yr

WEIGHT

8.1kg

INTERPRETED BY

R. McKenzie Daniel,
DVM, DABVP
(Canine and Feline)

IMAGING PERFORMED BY

Dr Sarah Barthelemy

HOSPITAL NAME

Fish Creek Pet Hospital

REFERRING VET

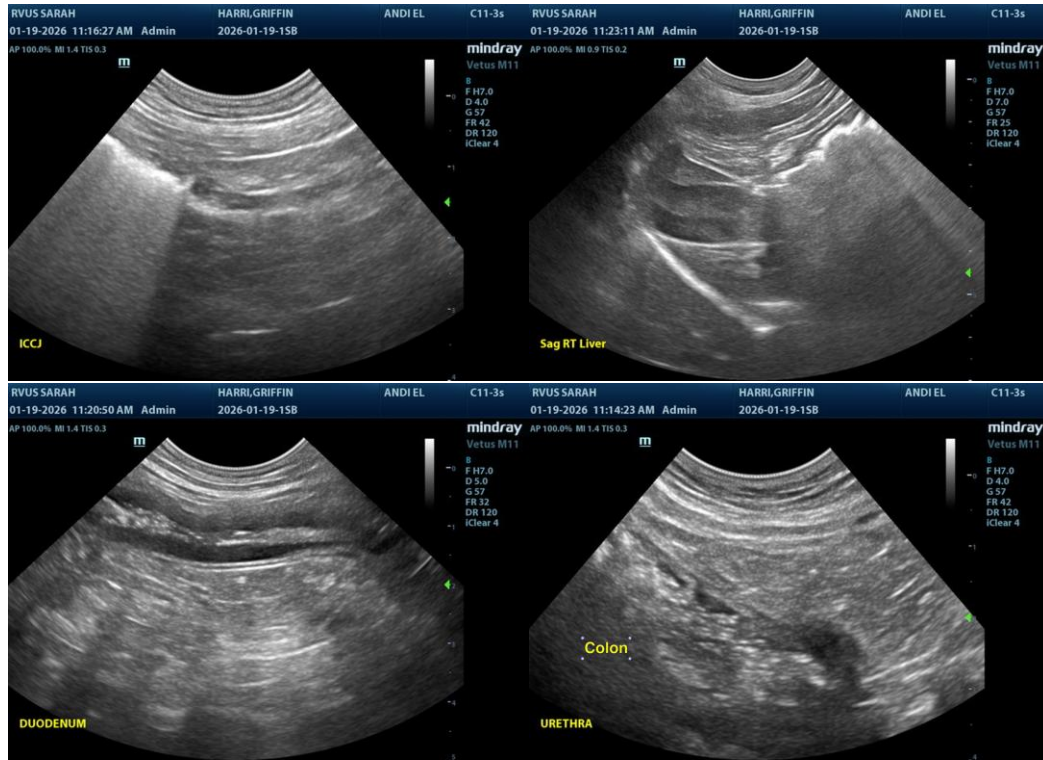
Dr McKay

INVOICE

23610

DATE

01/19/2026



The information and recommendations provided are based on the images presented by the referring veterinarian/sonographer. No evaluation can be communicated regarding pathology that was not visible in the image/video clips provided.

Thank you for this referral. If the clinical or image interpretation does not parallel your findings or if I can be of any further assistance, please contact me.

R. McKenzie Daniel, DVM, DABVP (Canine/Feline Practice)
info@sonopath.com